



OTCQB:VYCO

Corporate Presentation

2025

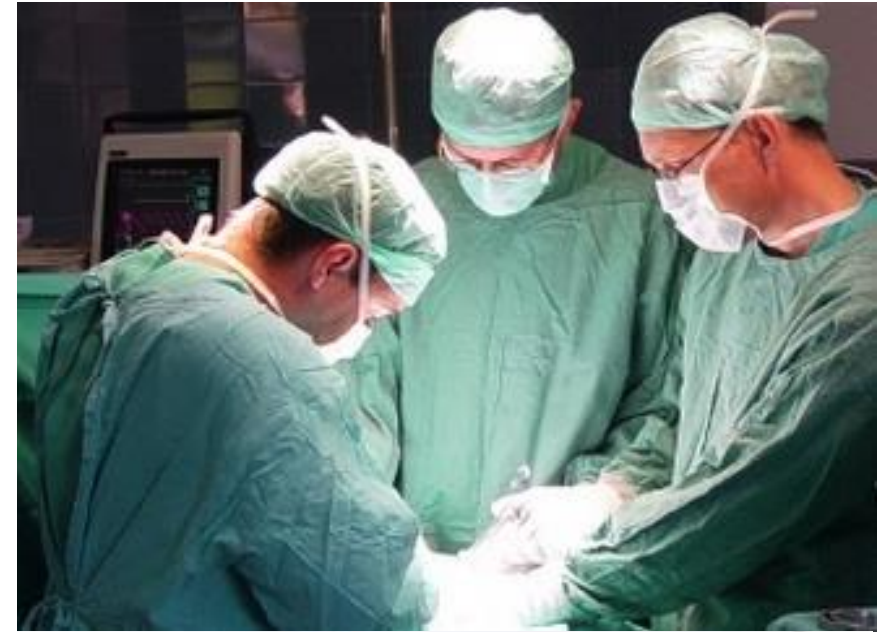Safe Harbor Statement



Information in this document constitute forward-looking statements or statements which may be deemed or construed to be forward-looking statements within the meaning of the Private Securities Litigation Reform Act of 1995. The words "forecast", "anticipate", "estimate", "project", "intend", "expect", "should", "believe", and similar expressions are intended to identify forward-looking statements. These forward-looking statements involve, and are subject to known and unknown risks, uncertainties and other factors which could cause VYCOR MEDICAL's actual results, performance (financial or operating) or achievements to differ from the future results, performance (financial or operating) or achievements expressed or implied by such forward-looking statements. The risks, uncertainties and other factors are more fully discussed in VYCOR'S SEC filings. All forward-looking statements attributable to VYCOR herein are expressly qualified in their entirety by the abovementioned cautionary statement. VYCOR disclaims any obligation to update forward-looking statements contained in this estimate , except as may be required by law. The recipient acknowledges that Vycor Medical, Inc. is a publicly traded company. Recipient acknowledges that any confidential information constituting material nonpublic information that Vycor Medical, Inc. provides to the recipient is being provided to the recipient in reliance upon the agreement that the information will remain confidential. By accepting this material, the recipient acknowledges that it is aware of the applicable requirements of the federal securities laws relating to material non-public information and trading in securities of Vycor Medical, Inc.

Who We Are

- Vycor Medical is dedicated to providing the medical community with innovative and superior **surgical** and **therapeutic solutions**.
- We have a portfolio of **FDA cleared** medical solutions that are changing and improving lives every day.
- Our main product lines are: **ViewSite™** and NovaVision's **VRT, NEC, and VIDIT** all of which adopt a minimally or non-invasive approach.



Our Two Product Lines

ViewSite™

Lead product ViewSite™ Brain Access System (VBAS) is a revolutionary neurosurgical device used to retract and gain access to a target within the brain e.g. tumor, other pathologies and other matters such as bullets or shrapnel fragments



NovaVision®

NovaVision has a family of complementary therapies that diagnose (VIDIT) and both **restore** (Visual Restoration Therapy® “VRT”) and **compensate** (NeuroEyeCoach™) for vision disorders as a result of stroke or brain damage. VRT is the **only FDA-cleared therapy** for the restoration of this type of vision loss; however significant further development is needed to address market potential.



Vycor Medical's Strategic Vision



Vycor Medical's Strategic Vision

Vycor Medical's Strategic Vision - Overview



Vycor's near term corporate strategic objective is to gain the critical mass and growth profile required to uplist to a recognized exchange through acquisitions and mergers

Vycor is well placed as a platform to deliver this objective:

- OTCQB listed and SEC reporting entity (went public through an S1).
- Management with background in mergers, integration and operation.
- Broad distribution nationally and internationally
- Financial and accounting, which can be leveraged
- Regulatory, with ISO 13485:2016, MDSAP (Medical Device Single Audit Program), FDA, EU and Health Canada in-house capability.
- Legal and IP

Vycor Medical's Strategic Vision – Vycor



Vycor's VBAS is a high margin niche medical device viewed as a “must have” by neurosurgeons for certain procedures. **This gives Vycor tremendous reach and strength in distribution of existing and new products and a quality cachet for products neurosurgeons can trust:**

- Approved for use in over 300 hospitals in the US, operating through a network of specialist surgical reps
- Approved in numerous internationally, operating through specialist surgical distributors, the largest in terms of volume being Japan, Canada, UK and the EU
- Strong KOL relationships
- Continuous product improvements and organic development of new products

Vycor Medical's Strategic Vision – NovaVision



NovaVision is revenue generating with validated products that provide an unmet need with an opportunity for growth and is well-positioned in the fast-growing global trend towards digital health and telehealth – however requires significant therapy and delivery development to capture its true potential.

Vycor's strategic focus for NovaVision is:

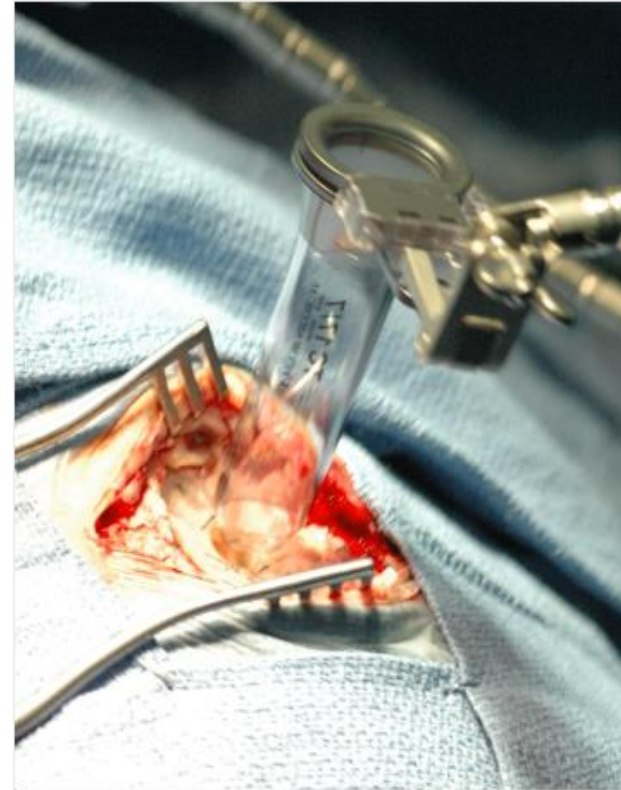- Delay development until Vycor is uplisted and able to raise robust funding for its development including regulatory approval and explore reimbursement or
- Identify a partner to take the business forward, particularly in assisting with further therapy and product delivery development. An entity focused on digital health/telehealth and non-medical opportunities would also be a good fit.

ViewSite™ Brain Access System (VBAS)

ViewSite™ Brain Access System (VBAS)

“It is the ideal system for providing deep brain access through a smaller incision.”

-Neurosurgeon Quote



ViewSite™ : The Future Standard of Care

- Less brain tissue damage
- Less invasive: requires smaller opening
- Better access
- Better visibility
- Self-contained working channel
- Reduced operating and recovery time

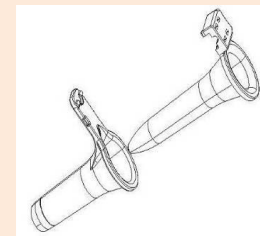
Allows for use in procedures previously considered inoperable, saving lives

Old Blade/Ribbon Retractor Technology



VS.

VBAS Next Generation Technology



VBAS is a Step Change Improvement. Incumbent Technology Hasn't Changed in Over 50 Years

Market and Clinical Need for VBAS

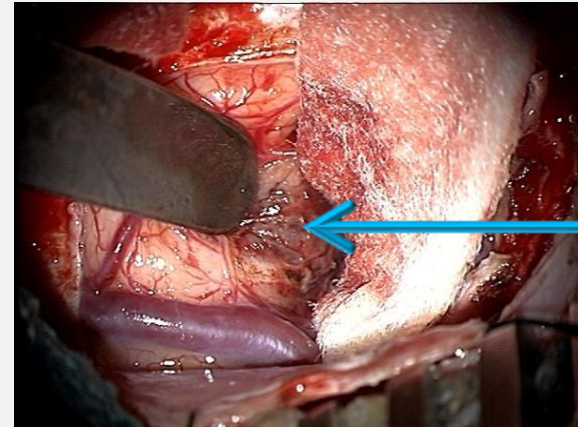


- Since the introduction of the first operative microscope 50+ years ago, microsurgery (and more recently endoscopic surgery) has become an indispensable technique in neurosurgery
- In any surgical procedure adequate visualization of the operative field is critical
- The standard of care has hitherto been so-called ribbon/blade retractors used to create and maintain visual corridor to access targets within the brain (Greenberg, Leyla and Budde Halo retractor systems)
- The brain like other sensitive tissue is subject to injury from retraction – most evident BUT NOT LIMITED TO approaches to deep-seated intracranial lesions

There was and remains a compelling need for VBAS

Superior Shape

- The VBAS tubular shape disperses retraction forces over a greater surface area and has no edges where pressure build up is most common
- Blunt tip allows for progressive dilation that permits the splitting of white matter rather than its transection
- Lower risk of Ischemic complications and results in faster wound healing and shorter patient recovery period
- Surgeon feedback also points to shorter OR time as no target shift issues through pulling, less consumables needed and greater ease of use



Discoloration of tissue near the retractor tip

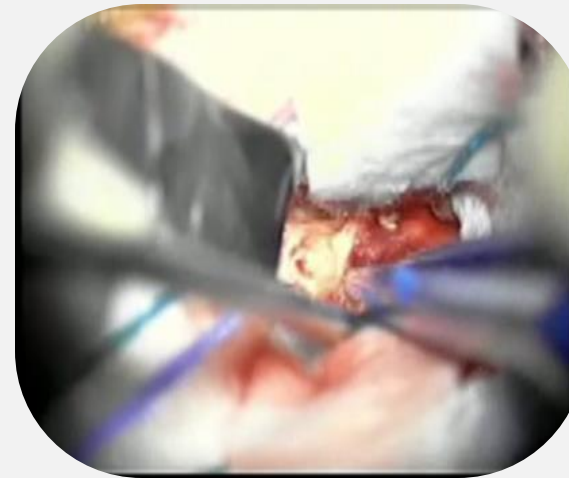
How VBAS Addresses the Market's Clinical Needs

Superior Field of View

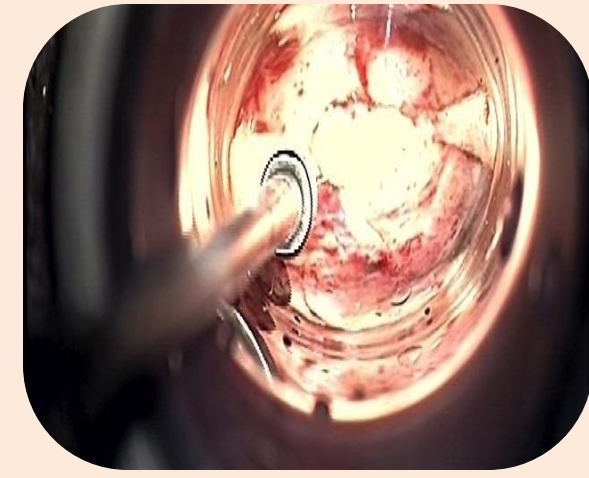
- Made of polished transparent polycarbonate
- Significantly increases the surgeon's vision through clear walls
- Allows for continual monitoring of surrounding tissue and structures during insertion and surgery
- Coated in biocompatible non-reflective ink does not suffer from reflection issues experienced with other retractors

Surgical Field of View

Standard Retractor



VBAS



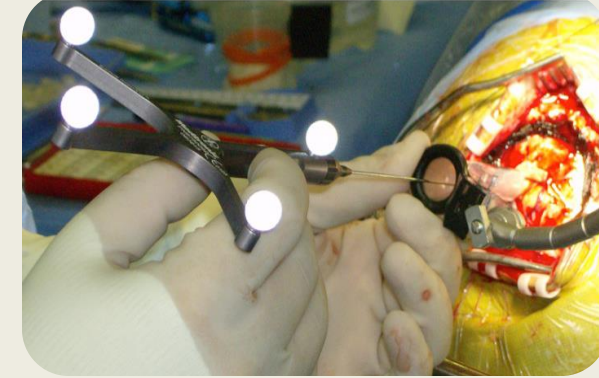
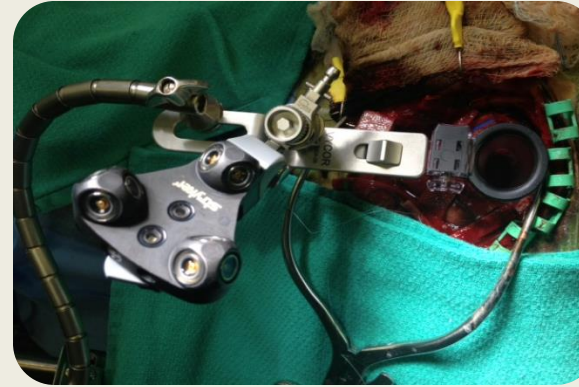
Improved Working Channel

- Elliptical shape provides a widened working channel in one access, gives the surgeon greater working room allowing for bimanual surgical maneuvering
- The contained working channel provides protection of peripheral anatomy from inadvertent instrumental or thermal damage
- Provides an air instead of CSF medium that provides better intra-operative visualization

How VBAS Addresses the Market's Clinical Needs

Compatible with Neuronavigation

- The tip of the VBAS introducer literally becomes the “pointer” on the neuro-navigation system, allowing for real time monitoring of its position
- Clip of the VBAS AC locks in place the most commonly used neuro-navigation pointers



VBAS Saves Lives

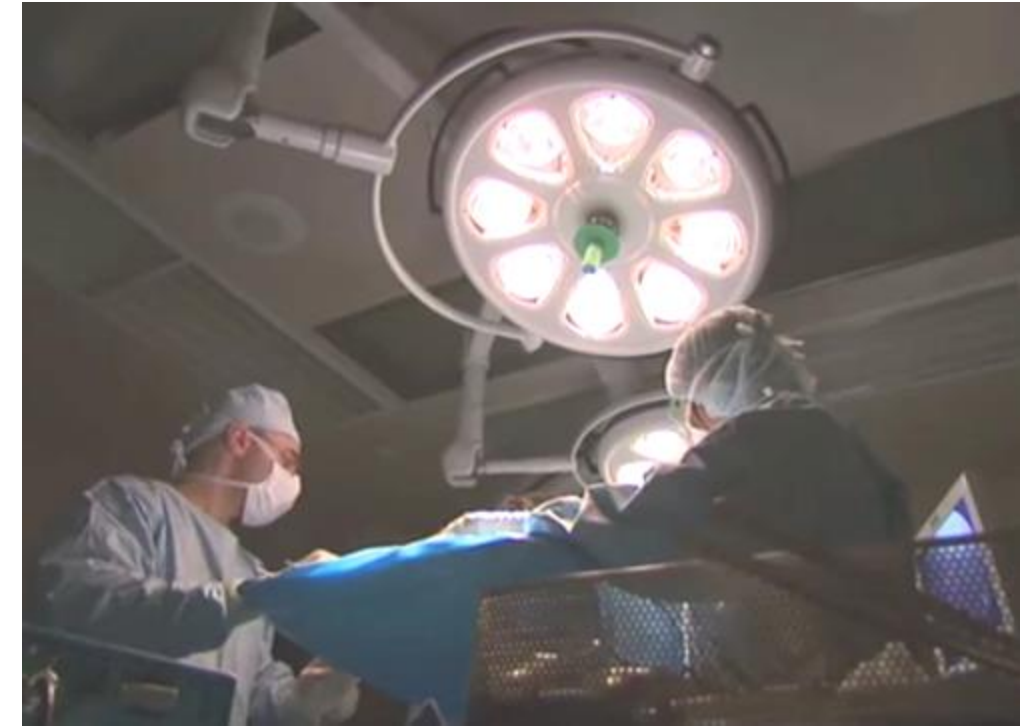Previously Inoperable...Now Operable

“Her case would have been inoperable via a traditional surgery, because she was taking Avastin®, which delays surgical wound healing.

“The VBAS’ minimally invasive nature enabled the surgeon to gain access to the target through only a 3cm incision.

“The patient was discharged uneventfully and there were no issues regarding her wound.”

– Daniel Prevedello, MD, Director of the Minimally Invasive Cranial Surgery Program, Ohio State University



Bullet fragment removal

“We would not have attempted this without this technology. It’s very exciting”

– Narayan Sundaresan, MD, Chief Neurosurgeon at Lincoln Medical Center, NY, and Professor at Mount Sinai Hospital, NYC



Benefits Evidenced Through Extensive Clinical Data



- Build up of clinical evidence to support the VBAS advantages has been a key management objective
- VBAS has now been the subject of over 40 peer reviewed studies and numerous other clinical papers involving over 500 patients
- Studies now conclusively point to reduced white matter damage and better patient outcomes, shorter post-operative hospital stay adding to neurosurgeon comments of reduced OR time

= IMPROVED PATIENT OUTCOMES

= REDUCTION OF HOSPITAL COSTS


Strong Body of Clinical Data Supporting VBAS Superiority

ICH New Exciting Opportunity



OTCQB:VYCO

- Increasing Focus on ICH Evacuation Utilizing Tubular Retractors - Opening a Large New Opportunity



Technical Notes

Minimally invasive craniotomy for putaminal hemorrhage using a tubular retractor: A technical note

Takuto Kawajima¹, Mikiya Beppu¹, Shinichi Yoshimura²

¹Department of Neurosurgery, Saiseikai Nee Hospital, Osaka, ²Department of Neurosurgery, Hyogo Medical University, Nishinomiya, Japan.
E-mail: *Takuto Kawajima - takuto01@gmail.com; Mikiya Beppu - mikiya.beppu@gmail.com; Shinichi Yoshimura - hyogoneuro@yahoo.co.jp



*Corresponding author:
Takuto Kawajima,
Department of Neurosurgery,
Saiseikai Nee Hospital, Osaka,
Japan.
takuto01@gmail.com

Received: 07 April 2024
Accepted: 09 May 2024
Published: 21 May 2024

DOI
10.25259/SNI_285_2024

Video available on:
https://doi.org/10.25259/SNI_285_2024

Quick Response Code:



This is an open-access article distributed under the terms of the Creative Commons Attribution-Non-Commercial-Share Alike 4.0 License, which allows others to remix, transform, and build upon the work non-commercially, as long as the author is credited and the new creations are licensed under the identical terms.
© 2024 Published by Scientific Scholar on behalf of Surgical Neurology International

Acta Neurochirurgica (2023) 165:1597–1602
<https://doi.org/10.1007/s00701-022-05236-3>

HOW I DO IT - VASCULAR NEUROSURGERY - OTHER

Minimally invasive image-guided endoscopic evacuation of intracerebral haemorrhage: How I do it

Tim Jonas Hallenberger^{1,2} · Raphael Guzman^{1,2} · Jehuda Soleman^{1,2}

Received: 2 May 2022 / Accepted: 24 July 2022 / Published online: 5 August 2022
© The Author(s), under exclusive licence to Springer-Verlag GmbH Austria, part of Springer Nature 2022

Abstract Background Minimally invasive endoscopic hematoma evacuation (MEHE) is an emerging surgical technique for treating spontaneous supratentorial intracerebral haemorrhage (SSICH). Multiple studies, analysing whether the outcome after such a procedure is improved, are still ongoing.
Method We herein present the indications, advantages, and perioperative considerations for the surgical technique of MEHE applied at our institution.
Conclusion MEHE with a view through a transparent brain access device is a valid and safe approach for the surgical evacuation of SSICH.

Keywords Neurosurgery · Endoscopic surgery · Intracerebral haemorrhage · Minimally invasive surgery · Haemorrhagic stroke

Introduction

Spontaneous supratentorial intracerebral haemorrhage (SSICH), with an incidence of 24.6 per 100,000 persons-years, leads to devastating mortality and morbidity rates [8]. SSICH is most commonly caused by hypertension or amyloid angiopathy [9]. Responsible for the brain injury are the primary damage caused by the bleeding itself, the perifocal oedema, the toxic breakdown products of haemoglobin, and the concomitant inflammation, resulting in poor outcome for 61–88% of the patients [8, 9]. Since the STICH trials failed to show an advantage of surgical evacuation by craniotomy (CC), surgical treatment remains controversial, while best medical treatment (BMT) remains the current gold standard [2, 4, 5].

Minimally invasive surgery however appears promising, especially minimally invasive endoscopic hematoma evacuation (MEHE) seems to ameliorate functional outcome and survival rates among patients with SSICH [7].

This article is part of the Topical Collection on Vascular Neurosurgery - Other

✉ Jehuda Soleman
jehuda.soleman@gmail.com

¹ Department of Neurosurgery, University Hospital Basel, CH-4031 Basel, Switzerland
² Faculty of Medicine, University of Basel, CH-4056 Basel, Switzerland

In this project, we have shown that by using the Vycor retractor system we had a significant intracerebral hematoma volume reduction. This is a novel, simple and affordable technique for the management of patients with intracerebral hemorrhage in rural hospitals.

LITERATURE REVIEW

Check for updates

Use of Vycor Tubular Retractors in the Management of Deep Brain Lesions: A Review of Current Studies

Stephan Z. Shapiro¹, Kenneth A. Sabacinski¹, Samuel A. Mansour¹, Nikolas B. Echeverry¹, Sumedh S. Shah¹, Alan A. Stein¹, Brian M. Snelling¹

Key words

- Cyst
- Foreign body
- Hematoma evacuation
- Intra-axial
- Retractor
- Tubular retractor
- Tumor resection

Abbreviations and Acronyms

GTR: Gross total resection
PRISMA: Preferred Reporting Items for Systematic Reviews and Meta-Analyses
STR: Subtotal resection
VBAS: ViewSite Brain Access System

From the Departments of Student Affairs, Florida Atlantic University Charles E. Schmidt College of Medicine, Boca Raton, Florida, ¹University of Miami Miller School of Medicine, Miami, Florida, ²Department of Neurological Surgery, New York Medical College, White Plains, New York, and ³Maricopa Neuroscience Institute, Boca Raton Regional Hospital, Boca Raton, Florida, USA

In whom correspondence should be addressed:
Brian M. Snelling, M.D.

E-mail: bsnellin@fau.edu
Clin Exp Neurol Neurosurg (2024) 132:283–290

<https://doi.org/10.1016/j.cen.2023.09.017>

Journal homepage: www.elsevier.com/locate/clinexpneurol

Available online: www.elsevier.com/locate/clinexpneurol

1678-8750 - see front matter © 2019 Elsevier Inc. All rights reserved.

INTRODUCTION

Resection of lesions located within deep intracranial and intraventricular sites requires brain retraction. Traditionally, retraction during resection of deep-seated lesions was accomplished using flat blades or paddles. However, traditional manually held retraction has been shown to cause secondary parenchymal damage.^{1–3} Parenchymal damage from standard retraction has been related to vascular compromise because of structural shifting, disruption of normal blood flow, and rupture of small capillary beds caused by increased localized pressure and direct parenchymal trauma.^{4–6} On

the other hand, the use of self-sustaining retractors has been associated with increased cerebrovascular trauma secondary to increased torque on abutting tongs or Mayfield anchored systems, traditional plate retraction still causes significant secondary parenchymal damage. As a result, other strategies to minimize disruption of normal brain have evolved, such as self-sustaining retractors, neuronavigation, and endoscopic approaches. Recently tubular retractors, such as the ViewSite Brain Access System (VBAS), have been developed to reduce mechanical damage from retraction by dispersing the force of the retractor radially over the parenchyma. Therefore, we sought to review the current literature to accurately assess the indications, benefits, and complications associated with use of VBAS retractors.

METHODS: A literature search for English articles published between 2005 and 2019 was performed using the MEDLINE database archive with the search terminology “Vycor OR ViewSite OR Brain-Access-System NOT glass.” The VBAS website was also examined. Only articles detailing neurosurgical procedures using the VBAS tubular retractor system alone, or in combination with other retractors, were included. Postoperative morbidity and mortality were analyzed to estimate complications linked to using the retractor.

RESULTS: Twelve publications (106 patients) met the inclusion criteria. The VBAS retractor was used for tumor resections, hematoma evacuations, cyst removal, foreign body extractions, and lesion resection in toxoplasmosis and multiple sclerosis. These cases were subdivided into groups based on lesion location, size, and resection volume for further analysis. Gross total resection was achieved in 63% of tumor excisions, and subtotal resection was achieved in 37%. Hematoma evacuation was successful in all cases. There were 3 short-term postoperative complications linked to the retractor, with an overall complication rate of 2.8%.

CONCLUSIONS: This report is the first formal assessment of the VBAS, highlighting technical considerations of the retractor from the surgeon’s perspective, patient outcomes, and complications. The retractor is a safe and efficacious tubular retraction system that can be used for tumor biopsy and resection, colloid cyst removal, hematoma evacuation, and removal of foreign bodies. However, further randomized controlled trials are indicated to accurately assess complication rates and outcomes.

the other hand, the use of self-sustaining retractors has been associated with increased cerebrovascular trauma secondary to increased torque on abutting tongs or Mayfield anchored systems, traditional plate retraction still causes significant secondary parenchymal damage. As a result, other strategies to minimize disruption of normal brain have evolved,



ICH New Exciting Opportunity - continued

TECHNICAL NOTE



Fully Endoscopic Freehand Evacuation of Spontaneous Supratentorial Intraparenchymal Hemorrhage

Filippo Flavio Angileri, Felice Esposito, Stefano Maria Priola, Giovanni Raffa, Daniele Marino, Rosaña Viola Abbritti, Maria Giusa, Antonino Germano, Francesco Tomasello

OBJECTIVE: A modification of other reported endoscopic techniques for intracerebral clot evacuation is described and illustrated.

METHODS: From January 2014 to December 2014, we operated on 6 patients harboring a spontaneous supratentorial intracerebral hemorrhage using a fully endoscopic freehand technique. Clinical chart and surgical videos were analyzed. Volumetric evaluation of the clot preoperatively and the residual hematoma postoperatively was performed. Clinical outcome was measured using the modified Rankin Scale and Glasgow Outcome Scale.

RESULTS: The mean operative time was 96 minutes (range, 72–125 minutes). Clot evacuation was >90% in all patients. No patient experienced rebleeding after surgery. Two patients died. The Glasgow Outcome Scale score at 6 months was 4 in 2 patients, 3 in 2 patients, and 1 (death) in 2 patients. The modified Rankin Scale score at 6 months was 6 (death) in 2 patients, 4 in 2 patients, 3 in 1 patient and 2 in 1 patient.

CONCLUSIONS: The proposed minimally invasive technique allows a good rate of hematoma evacuation and intraoperative bleeding control. Further studies in large series are needed to confirm the role of this freehand endoscopic technique.

INTRODUCTION

Spontaneous intracerebral hemorrhage (ICH) is the second most frequent form of stroke and carries the worst prognosis.¹ Surgical evacuation of supratentorial ICH is

currently performed in most neurosurgical departments; it is the second most common nontraumatic cerebral emergency in neurosurgical practice.^{1,2} Nevertheless, its efficacy is not proven for both deep and lobar hematomas.^{3,4} The most recent American Heart Association guidelines state that for most patients with supratentorial ICH, the usefulness of surgery is not well established (class IIB; level of evidence A), and the effectiveness of minimally invasive clot evacuation with stereotactic or endoscopic aspiration with or without thrombolytic usage is uncertain (class IIB; level of evidence B).⁵

An effective and reliable method for minimally invasive clot evacuation in supratentorial ICH is still missing. We report a modification of other already proposed endoscopic techniques of clot evacuation based on a fully endoscopic freehand procedure.

MATERIALS AND METHODS

Over a 12-month period, we operated on 6 patients harboring a spontaneous supratentorial ICH using a fully endoscopic technique. Clinical charts and surgical videos were analyzed. There were 4 male patients and 2 female patients with a mean age of 64 years (range, 58–72 years). Preoperative Glasgow Coma Scale score was ≤ 8 in 4 patients and > 9 in 2 patients. One patient was admitted with a Glasgow Coma Scale score of 14 but rapidly deteriorated to a score of 11. All patients underwent emergency computed tomography (CT) scan and were operated on following a neurosurgical consultation (Figures 1 and 2). CT angiography was performed in selected cases. The mean preoperative ICH volume was 74.8 mL (range, 60–105 mL). All patients underwent clot evacuation by a fully endoscopic freehand technique. Postoperative CT was performed 4 hours after surgery (Figures 1 and 2) and then as needed according to the patient's clinical condition. The amount of residual clot was evaluated on the first postoperative CT scan. Patients were

Key words
 ■ Endoscopic management
 ■ Intraparenchymal hemorrhage
 ■ Stroke
 ■ Surgical treatment

Abbreviations and Acronyms
 CT, Computed tomography
 ICH, Intracerebral hemorrhage

Division of Neurosurgery, Department of Biomedical and Dental Sciences and Morphofunctional Imaging, University of Messina, Messina, Italy

To whom correspondence should be addressed: Filippo Flavio Angileri, M.D., Ph.D.
 [E-mail: angileri@unime.it]

Citation: World Neurosurg (2015) 84,268-272.

http://dx.doi.org/10.1016/j.wneu.2015.07.035

Supplementary digital content available online.

Journal homepage: www.WORLDNEUROSURGERY.org

Available online: www.sciencedirect.com

1878-7503/\$ - see front matter © 2015 Elsevier Inc. All rights reserved.



INTERNATIONAL FEDERATION OF NEUROENDOSCOPY IFNE VII WORLD CONGRESS OF NEUROENDOSCOPY The Westin Resort & Spa Puerto Vallarta November 1st to 4th, 2015



SINGLE-PORT ENDOSCOPIC TECHNIQUE FOR THE TREATMENT OF PRIMARY INTRACEREBRAL HEMORRHAGE

JUAN ANTONIO PONCE-GÓMEZ M.D., LUIS ALBERTO ORTEGA-PORCAYO M.D., VÍCTOR ALCOCER-BARRADAS M.D., JUAN BARGES-COLL M.D., JUAN LUIS GÓMEZ-AMADOR M.D.
 DEPARTMENT OF NEUROLOGICAL SURGERY, NATIONAL INSTITUTE OF NEUROLOGY AND NEUROSURGERY "MANEL VELÁSQUEZ SUÁREZ", MEXICO CITY, MEXICO

INTRODUCTION

Intracerebral hemorrhage accounts for 10-15% of cerebrovascular disease and is associated with increased morbidity and mortality. Intracerebral hemorrhage is considered a neurosurgical emergency, but to date there is no general agreement on the selection of the type of treatment for these patients, especially in the case of supratentorial hematomas.

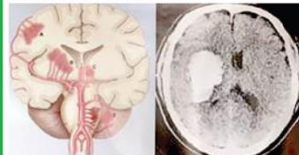


Fig 1 Most common sites of intracerebral hemorrhage.

OBJECTIVE

Analyze outcome, morbidity and mortality between three different types of treatment for supratentorial primary intracerebral hemorrhage.

MATERIALS AND METHODS

A retrospective case series with the diagnosis of primary supratentorial intracerebral hemorrhage were analyzed. Three different treatments were compared: medical management and observation, hematomas drainage through a single-port (endoport) with endoscopic assistance and drainage through a conventional craniotomy.

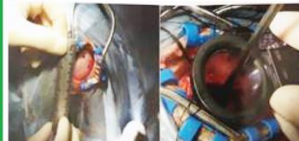


Fig 2 Craniotomy and endoport introduction.

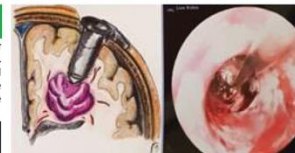

Fig 3 Endoscopic view of the drainage of the hematoma.

RESULTS

Clinical and radiological records of a total of 64 patients were analyzed, of whom 60.9% were men. The average age was 52.7 years (range 22-84 years). Medical treatment group was used in 28 patients, conventional craniotomy in 24 patients and single-port treatment in 12 patients. Hypertension was the main risk factor for the primary intracerebral hemorrhage. The main symptom was headache. The largest volume of bleeding was found in the endoport group with 66.3 cm³. The medical treatment group had more patients with a deep intracerebral hemorrhage (basal ganglia) (60.7%), while the craniotomy group had more patients with a lobar hemorrhage (70.8%). Complete drainage of the hematoma was achieved in 83.3% of cases from the endoport group. Patients treated using the endoscopic endoport technique had an average hospital stay of 8.08 days, with a statistically significant difference against the other two groups ($p = 0.003$). Mortality at 6 months had a significant difference between the medical treatment group and the endoport group, 42.9% vs. 0%, respectively ($p = 0.02$).

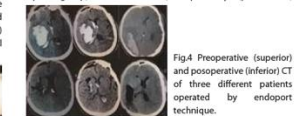


Fig 4 Preoperative (superior) and postoperative (inferior) CT of three different patients operated by endoport technique.

CONCLUSIONS

Treatment using the endoscopic single-port technique offers lower morbidity and fewer days of hospital stay in the management of primary supratentorial intracerebral hemorrhage

REFERENCE Mean references: 1. Mayer SA, et al. Rationale for Treatment of Intracerebral Hemorrhage. Lancet Neurol 2005; 4: 662-672. 2. Zuccarello M, Andruzik N, Wagner KR. Minimally Invasive Therapy for Intracerebral Hematomas. Neurosurg Clin N Am 2002; 14(3):339-349.



Available online at www.sciencedirect.com

ScienceDirect

Journal of the Chinese Medical Association 78 (2015) 101–107



www.jcma-online.com

Original Article

Endoscopic hematoma evacuation in patients with spontaneous supratentorial intracerebral hemorrhage

Wei-Hsin Wang^{a,b}, Yi-Chieh Hung^a, Sanford P.C. Hsu^{a,b}, Chun-Fu Lin^{a,b}, Hsin-Hung Chen^{a,b}, Yang-Hsin Shih^{a,b}, Cheng-Chia Lee^{a,b,c,d,e}

^a Department of Neurosurgery, Neurological Institute, Taipei Veterans General Hospital, Taipei, Taiwan, ROC

^b National Yang-Ming University School of Medicine, Taipei, Taiwan, ROC

^c Department of Neurosurgery, Hsinchu Branch, Taipei Veterans General Hospital, Hsinchu, Taiwan, ROC

Received October 4, 2013; accepted August 13, 2014

Abstract

Background: Surgical evacuation of spontaneous supratentorial intracerebral hemorrhage (ICH) is controversial because the traditional surgical approach sometimes causes further brain injury. The introduction of the neuroendoscope has brought with it the new idea of minimal invasiveness, which may improve the surgical results of ICH.
Methods: Twenty-one patients with spontaneous supratentorial ICH underwent endoscopic hematoma evacuation between December 2010 and January 2012. Safe entry points could be Kocher's, Keen's, or Frazier's point, depending on the locations of the hemorrhages. The surgical steps were as follows: (1) cortical incision and dilation of the channel; (2) introduction of the transparent sheath; (3) gushing out of the hematoma under high intracranial pressure; (4) changing the angle of the transparent sheath, endoscope, and suction tip to remove residual hematoma; and (5) paving a layer of hemostatic agents after hematoma removal.

Results: The median operative time was 120 minutes (range: 90–190 minutes), and the median blood loss was 160 mL (range: 50–300 mL). The median duration of intensive care unit stay was 6 days (range: 2–18 days). The median hematoma evacuation ratio was 90% (range: 60–99%). Two patients had rebleeding events, and the mortality rate was 9.5% ($n = 2/21$). The median Glasgow Coma Scale score improved from 8 to 11 within 1 week after surgery, and the median Glasgow Outcome Scale score was 3 after 6 months and 12 months follow-up.

Conclusion: With the introduction of the minimally invasive techniques and the evolution of the neuroendoscope and hemostatic agents, the median operative time and blood loss have been significantly decreased. Although the hematoma evacuation rates were similar between the endoscope (90%) and craniotomy (85%) groups, the median intensive care unit stay was decreased from 11 days to 6 days due to reduced surgical invasiveness. This represents an important advancement in treating spontaneous supratentorial ICH, and provides a measured preview of the promising results that can be expected in the future.

Copyright © 2014 Elsevier Taiwan LLC and the Chinese Medical Association. All rights reserved.

Keywords: Glasgow coma scale; Glasgow outcome scale; Neuroendoscopy; spontaneous intracerebral hemorrhage; surgical evacuation

1. Introduction

Spontaneous supratentorial intracerebral hemorrhage (ICH) affects ~20 in 100,000 people annually and the mortality is >40%.¹ For the most part, survivors are left handicapped. Although the clinical outcome is mainly determined by the patient's initial presentation, early surgical intervention is crucial and urgent in selected patients. In the previous

Conflicts of interest: The authors declare that there are no conflicts of interest related to the subject matter or materials discussed in this article.

* Corresponding author: Dr. Cheng-Chia Lee, Department of Neurosurgery, Neurological Institute, Taipei Veterans General Hospital, 201, Section 2, Shih-Pai Road, Taipei 112, Taiwan, ROC.
 E-mail addresses: cckc12@vghtpe.gov.tw, yfmgshy@gmail.com (C.-C. Lee).

<http://dx.doi.org/10.1016/j.jcma.2014.08.013>

1726-4901/Copyright © 2014 Elsevier Taiwan LLC and the Chinese Medical Association. All rights reserved.

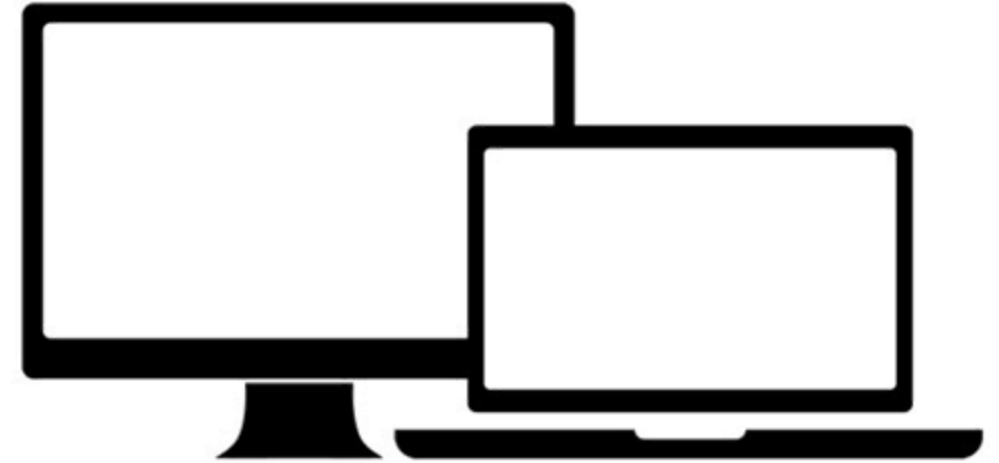Approved for Use in 350+ US Hospitals

- Significant body of clinical papers and studies evidence VBAS' clinical superiority and improved patient outcomes
- International presence with regulatory approvals in key international markets
- Technology protected by 46 granted and 11 pending patents in the US and internationally



Outsourced Business Model: Increases Efficiency

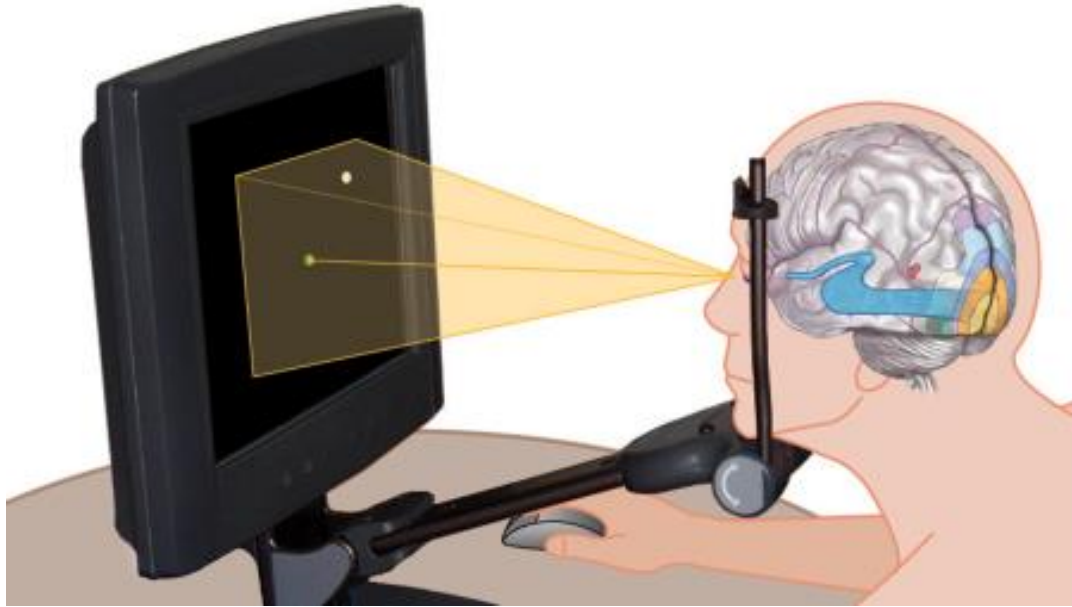
- Vycor focuses on product innovation, targeted marketing, and regulatory oversight, while outsourcing operations such as manufacturing and sales
- **Manufacturing:** outsourced to qualified sub-contract manufacturers
- **US sales:** outsourced to 11 distribution groups with a total of 104 reps who are experts in the neurosurgical device space, have local presence and are in the OR daily
- **International sales and marketing:** outsourced to leading distributors in each country/region focused on neurosurgical devices



This lean structure reduces fixed costs and enables Vycor to scale efficiently as demand for its products grows

NovaVision

NovaVision's Suite of Complementary Therapies Addresses Patients with Vision Disorders Resulting from Stroke or Brain Injury



During each therapy session, you fixate your eyes on a central point displayed on the computer screen. You press a button every time you see a light target appear.



“We do not need a new brain, but innovative methods of treatment to overcome the functional consequences of brain injury”

- Prof. Josef Zihl, Ph.D., Professor of Neuropsychology University of Munich

“VRT makes a world of difference. Every day I feel like I see a little better. This would not be possible without NovaVision. This is second time NovaVision saved my eyesight when no-one else would help. Your program is a life saver I can smile again.”

- Annette. MI. VRT and NeuroEyeCoach patient

An Important Therapy for Daily Life

“My vision began coming back after the first month of therapy...I passed my driving test, can read normally, and enjoy driving my boat on the lake...my life is back to normal.” – Stroke survivor and VRT patient



Pre-VRT



Post-VRT

The Impact on Daily Lives Can Be Meaningful, Enabling a Person to Be Home Alone, Cross the Road Unaided, Shop, Read & Even Drive

... And it Works

Clinically Demonstrated to Restore and Make the Most of Remaining Vision

- **VRT:** 15 years of research, 20 clinical studies including a 302 patient study in which notable improvements were seen in over 70% of the patients. Prescription-based, bespoke “at-home” therapy — **Not an App**
- **NeuroEyeCoach:** based on empirical evidence gained from several decades of research and 14 studies on a total of 591 patients
- 2020 definitive study by Universities of Aberdeen and Miami with 300 patients largest of its kind

Patient Success Stories

- Substantial body of testimonials from enthusiastic patients whose lives were changed
- Carol Urban, a former patient, interviews aired on 200+ US radio stations

“I can't put a value on what I have gained with NeuroEyeCoach, I can just say thank you with all that I am.”

- Luree- Virginia, U.S.

“VRT makes a world of difference. Every day I feel like I see a little better. This would not be possible without NovaVision.

This is second time NovaVision saved my eye sight when no-one else would help. Your program is a life saver I can smile again.”

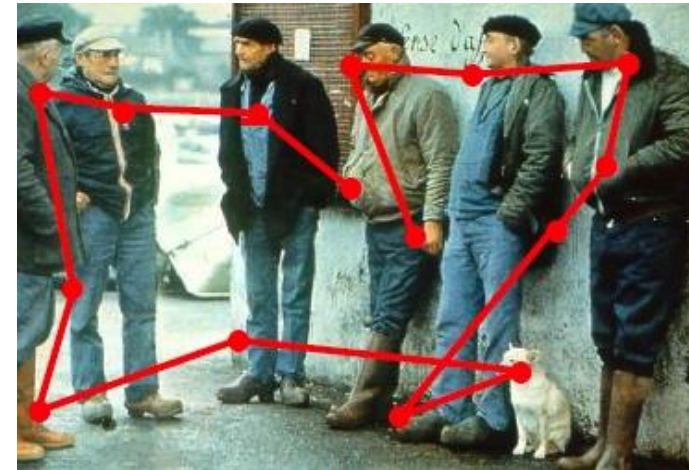
- Annette, a VRT and NeuroEyeCoach patient

NeuroEyeCoach Highly Effective

- The only dedicated visual training program specifically designed to improve scanning and eye movement:
 - Other scanning programs in use at clinics are part of aggregated modular systems
 - Can be completed during patient's stay in clinic or be completed at home under supervision



before training
(small eye shifts, many fixations; longer scanning time)



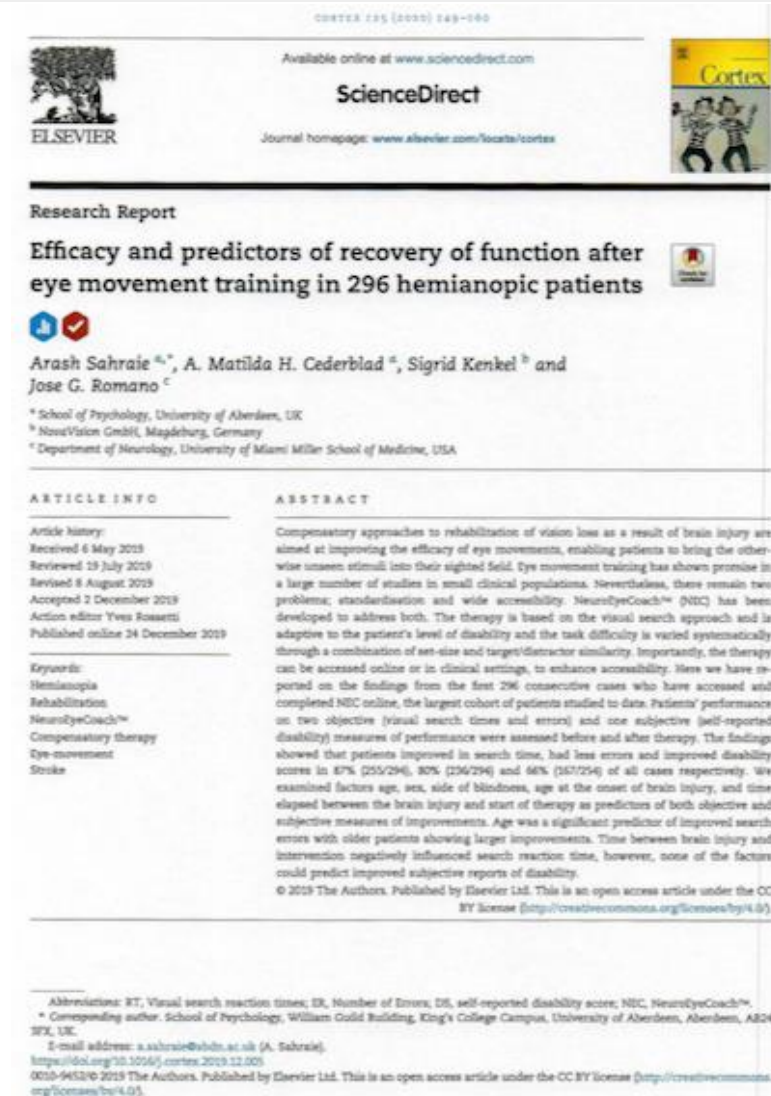after training
(larger eye shifts, less fixations, shorter scanning time)

NeuroEyeCoach Study

Published in *Cortex*, this is the largest study completed to date in the neuro visual space

- Analysed results of 296 patients who performed NeuroEyeCoach
- Demonstrated dramatic improvement in patients' ability to detect objects in the visual field by training them to make better eye movements
- Improved vision in over 80% of patients
- Improvements were not dependent on age, gender, side of blindness nor time elapsed since brain injury

Taken together with an earlier study published in *BioMed Research International*, they conclude the “NeuroEyeCoach can be viewed as being the first evidence-based gold standard registered medical device accessible to patients at home or in clinical settings which has a significant impact on patients' abilities to see things quickly with few errors”



VRT and NeuroEyeCoach are well suited capitalize on the global trend towards digital health: digitally delivered at-home treatment:

- Need to discharge patients from in-patient and out-patient facility care
- Health systems duty to provide care and rehabilitation
- At-home treatment for ageing population as preventative care

US Market Opportunity

- NovaVision estimates theoretical potential market to be significant
- Only real “competition” is lack of awareness and broad physician acceptance
- NovaVision’s scientific advisors believed that, with the required development outlined and correct KOL buy-in, the therapies should be able to capture 4-6% of the market: \$80-120 million

Significant Development is Required to Deliver on the Opportunities

NovaVision: Need for Further Development

The NovaVision therapies, while showing a positive impact on patients with visual field loss due to neurological damage, still require significant development to allow them to successfully address the multi-billion dollar market potential:

- Therapy needs to be adjusted to reflect KOL input, including possibly integrating TDCS which can increase magnitude and speed of recovery
- New clinical data needed on refined therapy
- Software needs to be updated for compatibility with all operating systems
- New delivery mechanisms to be evaluated, including use of goggles
- Possibility for reimbursement based on new clinical data
- New FDA clearance(s) required

These Steps Will Require Significant Spend and Take Several Years to Achieve

NEC Potential in Non-HealthCare Markets

NovaVision believes there is potential to move into non-healthcare markets possibly even through a JV:

- Strong potential for NeuroEyeCoach technology given its strong clinical data
- Potential variants for non-medical use in sports, aviation, gaming and security markets among others
- Medical applications in these sectors remains with NovaVision



Outside of NovaVision's healthcare focus could be a lucrative low-risk exploitation of its technologies

Company Contacts

Peter Zachariou, CEO

David Cantor, President

Adrian Liddell, CFO

Corporate Headquarters

951 Broken Sound Parkway,

Suite 320,

Boca Raton, FL 33487

561-558-2020

info@vycormedical.com

Our Websites

www.vycormedical.com

www.vycorvas.com

www.novavision.com